

AIS PennHIP

(877) 727-6800

www.antechimaging.com

Doctor's Copy

PennHIP Report

Referring Veterinarian: Dr Joseph Sutton

Email: mdvc@lakefield.net

Clinic Name: Memorial Drive Veterinary
Clinic

Clinic Address: 1415 Memorial Drive

Manitowoc, WI 54220

Phone: (920) 682-6558

Fax: (920) 682-6653

Patient Information

Client: Lauren, Teal

Patient Name: Eclipse

Reg. Name:

PennHIP Num: 148207

Species: Canine

Date of Birth: 25 Oct 2019

Sex: Female

Date of Study: 19 Oct 2020

Date of Report: 22 Oct 2020

Tattoo Num:

Patient ID: 23648

Registration Num:

Microchip Num: 977200009699862

Breed: GOLDENDOODLE CROSS

Age: 12 months

Weight: 18 lbs/8.2 kgs

Date Submitted: 19 Oct 2020

Findings

Distraction Index (DI): Right DI = 0.39, Left DI = 0.44.

Osteoarthritis (OA): No radiographic evidence of OA for either hip.

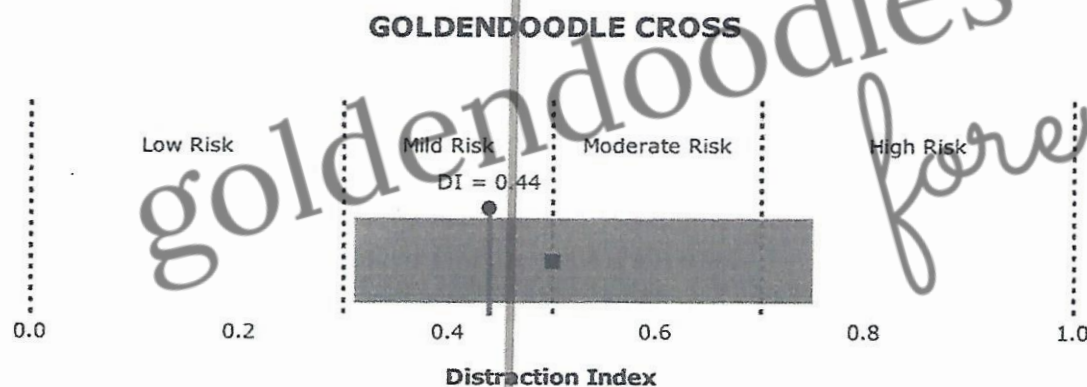
Cavitation/Other Findings: No cavitation present.

Interpretation

Distraction Index (DI): The laxity ranking is based on the hip with the greater laxity (larger DI). In this case the DI used is 0.44.

OA Risk Category: The DI is between 0.31 and 0.49. This patient is at mild risk for hip OA.

Distraction Index Chart:



BREED STATISTICS: This interpretation is based on a cross-section of 1876 canine patients of the GOLDENDOODLE CROSS breed in the AIS PennHIP database. The gray strip represents the central 90% range of DIs (0.31 - 0.75) for the breed. The breed average DI is 0.50 (solid square). The patient DI is the solid circle (0.44).